

To establish the role of HRCT in the early diagnosis of pulmonary disease in symptomatic HIV sero-positive patients with normal chest radiograph

Sudeena.D^{1*}, Ramaswamy², S.B. Lal³

¹Associate professor, department of pulmonary medicine, osmania medical college, Hyderabad, India

²Assistant professor, department of pulmonary medicine, osmania medical college, Hyderabad, India

³Professor, department of pulmonary medicine, Siddhartha medical college, Vijayawada, India

ABSTRACT

In our study of 352 HIV[2] seropositive patients with pulmonary symptoms, 34 patients had normal chest radiograph which is equivalent to 9.66% this value correlates with the study conducted by John Segreti *et al*, who demonstrated the chest radiograph were normal in 10% of his HIV patients with pulmonary symptoms. Among these 34 patients three patients did not turn up for further investigations. Hence only 31 patients were included in this study. In the present study 90.31% of patients belonged to the age group ranging from 20 – 40 years with a mean age of 30.3 years. As this is economically the most productive age group, early diagnosis and treatment of pulmonary disease decreased the morbidity and mortality and economic burden on the society. Palmieri F, Girandi E *et al*, in their retrospective study on 146 HIV[2] seropositive patients observed a decrease in survival among patients with pulmonary TB[1] negative sputum smear and normal chest X-ray at presentation. This was primarily attributed to the delay in the diagnosis of TB and initiation of antituberculosis treatment which results in faster progression of HIV infection. This highlights the importance of early diagnosis and treatment in symptomatic HIV seropositive patients with normal chest x-ray findings in India, where TB contributes the major share for the morbidity and mortality of HIV infection. In this study, lesions in the right and left lung were seen in 8 cases each and in both lungs in 16.12% cases. In the right lung, lesions were seen in 12.9% cases in the upper lobe, 6.45% in middle lobe and 6.45% cases in the lower lobe. In the left lung lesions were seen in 16.12% cases in the upper lobe, 6.45% cases in the lingual, in 3.22% cases in lower lobe. High resolution CT helps in localizing in the lung where further diagnostic investigations like bronchoscopy, bronchoalveolar lavage (BAL)[4] and fine needle aspiration cytology (FNAC) can be done wherever necessary. This observation was supported by Kirshenbaum KJ, Burke R *et al* in their study conducted in January 1998. In the present study the following were the CT findings consolidation in 4 cases (12.9%), fibrosis and bronchiectasis in 3 cases (9.67%) and blebs, bullae, ground glass appearance and hilar adenopathy in 1 case (3.22%) each. These findings can help us to suspect its diagnosis and guide us to select necessary specific, invasive and laborious investigations like bronchoscopy, BAL, FNAC, sputum culture for TB bacilli, staining for pneumocystis carinii etc. to come to a specific diagnosis. Gruden JF, Huang L *et al* in their study concluded that empirical therapy or immediate bronchoscopy can be avoided in many patients of PCP [3] on the basis of the HRCT findings.

Keywords: bronchogenic carcinoma, pulmonary TB, bronchoalveolar lavage [BAL] bronchoscopy, pneumocystis carini pneumonia, human immune deficiency virus.

Introduction

The three most important and common pulmonary complications of HIV[5] are TB, PCP and bacterial pneumonia, these comprise greater than 90% pulmonary complications worldwide. In developing countries, bacterial infections are of much greater importance, perhaps because these virulent infections

occur at an earlier stage in the disease before the profound immune – suppression required for PCP. The clinical and radiographic presentation of lung disease associated with HIV infection is non specific. Chest radiographic has limited sensitivity for the detection of early infection in immune compromised patients. The absence of radiographic findings, however, does not rule out pulmonary disease. In the patient respiratory complaint, PCP and TB must be considered even when the radiographic is normal. In up to 10% cases of TB and PCP chest radiograph is normal. CT scanning of chest, especially HRCT may be useful by revealing lesions not apparent on chest radiograph.

*Correspondence

Dr. Sudheena D, Associate professor,
Department of pulmonary medicine, osmania medical college, Hyderabad, India
E Mail: Drsudeenaravi@gmail.com

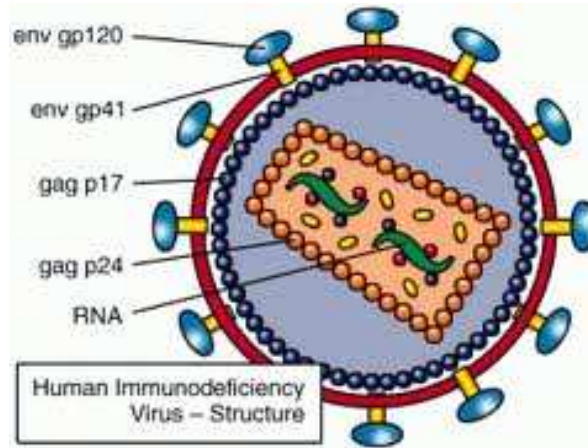


Fig 1: Human immunodeficiency virus

HIV poses special problems in the diagnosis of TB. With the spread of HIV every corner of Indian subcontinent, TB being the main opportunistic pulmonary infection contributing to mortality among HIV infections it is important to diagnose and treat early. More often it is presents in atypical forms with rapid progression. Though pulmonary TB is common form , extra pulmonary forms are increasingly seen in HIV and difficult to diagnose . In addition to these, sputum smear negative for AFB is more common in HIV ,TB patients . sputum smear examination is main stay of diagnosis in many underdeveloped countries , including india , and this smear negativity contributes to under diagnosis and delay diagnosis of TB[6] . The chances of MDRTB in HIV seropositive individuals are higher because of the increased bacillary load. They serve as reservoirs for MDRTB[6] in community leading to primary drug resistance even in non HIV patients . Epidemiologic and virologic and immunologic data support the premise that TB accelerates the course of HIV infection. So, early detection of the disease and treatment decrease the chances the MDRTB, slows the progression of HIV infection, decrease the morbidity and mortality and life span of the patients. PCP is not an uncommon infection

in Indians with advanced HIV . lack of recognition has probably been responsible for absence of any large series from this country . certain findings chest CT scans allow confident diagnosis of specific complications in patients with AIDS[9]. CT based diagnosed may preclude more invasive diagnostic procedures in selective cases . in some studies HRCT was shown more sensitive and more specific than gallium scintigraphy id diagnosing pulmonary disease early . HRCT have high positive and negative predictive values than gallium . HRCT IS MORE HELPFUL IN GUIDING THE method of biopsy directing the bronchoscopist to disease lung segment that would maximize diagnostic yield . In the early diagnosis of pulmonary disease in symptomatic HIV sero reactive patients with normal chest radiograph. The purpose of HRCT is to improve spatial resolution . several factors that effects this resolution are CT scanner specific and cannot be changed such as focal spots size the geometry and array detectors . there are a number of controllable factors , however , that affect the spatial resolution and quality of HRCT collimation , reconstruction algorithm , field of view , kVp ,maS , Window level and width.

Table 1: Revised CDC Classification System for HIV Infection and Expanded AIDS Surveillance Case Definition for Adolescents And Adults[7]

<i>Cd4 CELL COUNT CATEGORIES</i>	<i>Clinical categories</i>		
	<i>A</i>	<i>B</i>	<i>C</i>
$\geq 500\mu\text{L}$ or greater	A1	B1	C1
200-400 μL	A2	B2	C2
<200 μL (AIDS indicator, T cell count)	A3	B3	C3
<i>Asymptomatic HIV infection</i>	<i>Symptomatic, non A or C conditions (formerly AIDS related complex)</i>		<i>AIDS indicator (opportunistic conditions)</i>
Acute (primary) HIV infection	Bacillary angiomatosis		Candidiasis, pulmonary or esophageal
Persistent generalised lymphadenopathy	Candidiasis, oral or recurrent vaginal		Cervical cancer (invasive)
Acute retroviral syndrome.	Cervical dysplasia		Coccidioidomycosis
	Constitutional symptoms (such as fever or diarrhea) >1 month	Hairy leukoplakia, oral herpes zoster infection (>1 episode or >1 dermatome shingles)	Cryptococcosis, extrapulmonary
	Idiopathic thrombocytopenic purpura		Cryptosporidiosis > 1 month
	Listeriosis		Cytomegalovirus, chronic (>1month) or esophageal
	Pelvic inflammatory disease		Histoplasmosis
	Peripheral neuropathy		Isosporosis
			Kaposi's sarcoma
			Lymphoma
			Mycobacterium avium complex
			M.Kansasii
			M.Tuberculosis
			Pneumocystis carinii
			Pneumonia, recurrent
			Progressive multifocal leukoencephalopathy
			Salmonellosis
			Toxoplasmosis (CNS)
			Wasting due to HIV encephalopathy

Aims and objectives

To establish the role of HRCT in early diagnose of pulmonary disease in symptomatic HIV seropositive patients with normal chest radiograph .

Methods and materials

A Total of 352 cases with HIV infection and pulmonary complaints have been screened between January to January 2013 attending the pulmonary

medicine OP/WARD , govt general hospital , Vijayawada . 34 patients have pulmonary complaints with normal chest radiograph , out of which 31 patients were investigated . 3 patients did not turn up for follow up and investigation . only 31 are included in present study .

Following selection criteria are observed

Inclusion criteria :

1. HIV seropositive patients

2. symptomatic patients for lung disease – fever , cough , SOB , chest pain , right sweat , loss of appetite and weight etc
3. Normal chest radiograph

Exclusion criteria:

1. HIV Seronegative patients
2. Asymptomatic HIV seropositive patients
3. Patient with abnormal chest radiograph
4. Patient less than 12 years of age
5. Patients with other systemic disease like heart and CNS problems , dm etc..
6. Pregnant woman
7. Unco- operative patients

HIV seropositivity was confirmed at the government general hospital ,VCTC (voluntary& confidential counselling and testing center) where 3 different types of ELISA tests were performed to detect antibodies against HIV. All the cases were examined in detail as per proforma with special reference to respiratory system ,other systems were also examined in detail whenever it was found necessary.tn each case ,history of present and past illness was carefully enquired into so as to obtain a complete historical background of case .none of the patients were on antiretroviral therapy. After clinical examination all the patients were subjected to the following investigations:

- Chest x ray [12]pa view
- Blood HB %
- Total leukocyte count

- Differential count
- ESR
- Urine –albumin,sugar and deposits
- Blood sugars
- Serum creatinine
- Serum bilirubin
- SGPT
- Serum electrolytes
- Absolute lymphocyte count
- Mantoux skin test
- Sputum examination-gram stain,culture
- Afb smear examination (3 samples)
- Exercise oxygen saturation measurement
- HRCT [8]

A HRCT[13] scab of the chest was performed consisting of 1.5mm collimation section at 10mm interval reconstructed with a high spatial frequency algorithm. all scans was performed without intravenous contrast medical at suspended end inspiration with the patient in supine position .scans were reviewed at a setting appropriate for lung parenchyma and mediastinum .The chest radiotherapy and HRCT scans were evaluated radiologists who had no prior knowledge of the etiology and clinical features. The HRCT scans were reported without th e concurrent availability of the chest radiography. HRCT findings were correlated with clinical features and other investigations.

Statistical analysis

Table 2: Age Distribution

AGE { in years }	no. of cases	percentages of total n=31
12-20	1	3.22%
21 -30	18	58.06%
31- 40	10	32.25. %
41-50	2	6.45%

Table 3 :Sex Distribution

Sex	no. of cases	percentage {n=31}
Male	20	64.51%
Female	11	35.49%

Table 4: Clinical Presentation

Symptoms	no. of cases	percentage [N=31]
Cough	31	100%
Dyspnoea	8	25.80%
Fever	24	77.4%
Chest pain	4	12.90%
Other	10	32.25%

Table 5 : patients with normal and abnormal HRCTs

HRCT finding	no . of cases	percentage [N=31]
Abnormal ct	12	38.7%
Normal ct	19	1.3%

Table 6 : Montoux skin test results

Montoux skin test	male	female	percentage {n=31}
Positive [>5mm]	5	4	29%
Negative	15	7	71%

Table 7: HRCT findings

HRCT findings	no.of patients	percentage [n=31]	male %	female %
Blebs	1	3.22%	0[0%]	1 [3.22%]
Bullae	1	3.22%	1[3.22%]	0 [0%]
Consolidation [11]	4	12.9%	2[6.45%]	2[6.45%]
Infiltrations	2	6.45%	1 [3.22%]/	1 [3.22%]
Ground glass opacity	1	3.22%	1[3.22%]	0[0%]
Fibrosis	3	9.67%	3[9.67%]	0[0%]
Brochioectasis	3	9.67%	3[9.67%]	0[0%]
Hair adenopathy	1	3.22%	0[0%]	1[3.22%]

Discussion

The secondary pulmonary lobule as defined by miller refers to the smallest unit of lung enclosed by connective tissue septae. It is polygonal in shape , measuring approximately up to 10-25 mm in dm. in the centre of secondary pulmonary lobule are the pulmonary artery and bronchioles that supply the lobule . The pulmonary veins are the periphery of the lobule and lymphatics presents centrally and peripherally. Each lobule has 4-8 acini , each of which is supplied by terminal bronchioles . The acinus is the largest unit of lung composed of entirely structures that are involved in gas exchange.

Concepts of cortico medullary lung: According to this lung can be divided in to peripheral cortex and central medulla. This helps to differentiate between physiological difference between peripheral and central lung ultimately predicting the HRT distribution of some lung disease.

Peripheral and cortical lung: [10] cortical lung can be conceived as consisting two or three rows of well organized and well defined secondary pulmonary lobules, which together form a layer 3-4mm in thickness at lung periphery and along surfaces adjacent to fissures the lobules are relatively large in size, better defined , uniform and marginated by thick inter lobar

septa . bronchi and pulmonary vessels in lung cortex are relatively small . Lobules are uniform, cuboid appear like stones in roman arch .

Central or medullary lung : Pulmonary lobule in central lung are smaller and more regular in shape than in cortical lung and marginated by irregular septae that are thinner and less vessel defined . When visible they are hexagonal in shape but well defined lobules are uncommonly seen in normal objects. In contrast with peripheral lung peri hilar vessels and bronchi in the lung medulla are large and easily seen on HRCT[15].

HRCT pattern of lung disease:

Generally HRCT findings can be classified in to 4 large categories based on the appearance

1. Linear And reticular opacities
2. Nodules and nodular opacities
3. Increased lung opacity
4. Abnormalities associated with decreased lung opacity, including cystic lucencies ,emphysema , airway disease[14] .

In our study 1 case showed ground glass appearance in HRCT. The main complaint is this patient being dyspnoea . Patient was tachypnic , oxygen saturation is low . The patient was started on cotrimoxazole based on HRCT findings . the patient respond to treatment in

1 week . Gruden JF , Haung L *et al* confirmed that HRCT was 100% sensitive and 89%, specific with 90% accuracy in diagnosing PCP . Udwardia ZF , doshi AV *et al* concluded that PCP[16] is not uncommon infection in Indians with advanced HIV. Richards PJ , Riddel L *et al* showed that the use of HRCT may help avoid unnecessary delay in diagnosing PCP and allow early medical interventions . In 3 cases [9.67%] bacterial pneumonia was diagnosed based on the clinical features, HRCT and sputum cultures and treated with appropriate antibiotics. They respond to the treatment with in 1 week .In 19 patients normal chest x – ray[18] and HRCT[17] , the respiratory complaints might be due to upper respiratory infections or obstructive air way disease . They are treated symptomatically and they respond to treatment .

Conclusion:

1. In this study, 9.66% of the HIV seropositive patients with pulmonary symptoms had normal chest radiograph.
2. 38.7% of patients with normal chest radiograph and abnormal HRCT .
3. HRCT Is useful in detecting early lesions in HIV seropositive patients with pulmonary symptoms , with normal chest x- ray , so HRCT should be done in all HIV seropositive patients having pulmonary symptoms , with normal chest x ray as it may reveal additional information .
4. As most of the patients in the present study belong to young age group [mean age of 30.3 years] it is advisable to indicate HRCT in these patients for early diagnose and helping further investigations and management
5. HRCT can localize lesions in the lungs and helps further diagnostic accuracy in invasive investigations like bronchoscopy ,BAL[19], FNAC etc.
6. HRCT can help in suspecting a probable diagnose and start empirical treatment early before reaching a definitive diagnosis . so , it may be included in diagnostic algorithm in these patients before contemplating for invasive investigations .
7. TB is most common pulmonary infection in HIV seropositive patients with normal chest radiograph . early diagnosis can be suspected by HRCT
8. PCP can be diagnosed early on the basis of the HRCT findings even when the chest radiograph is normal .
9. centres for disease control and prevention 1993 revised classification system and expanded surveillance case definition for AIDS[20] among adolescents and adults.

Reference

1. A Ahidjo , H yusuph A Tahir *et al* radiographic features of pulmonary TB among HIV patients in Maiduguri , Nigeria . BMJ .2006; 332:1392
2. Barnes PF , LAkey DL burmann wj *et al* – TB in patients with HIV infection . infect dis clin north am 16:107 – 126 , 2002
3. Boiselle PM , tocino I , Hooley RJ *et al* : chest interpretation of pneumocystis carini pneumonia , bacterial pneumonia and pulmonary TB in HIV positive patients ; accuracy , distinguishing features , and mimics . J thorac imaging 1997 jan :12[1] 47-53
4. Broadus c , dake MD , stulbarg MD *et al* : bronchoalveolar lavage and trans bronchial biopsy for the diagnosis of pulmonary infections in acquired immune deficiency syndrome . ann intern med 102;747-752 , 1985.
5. Brucfield J Aderaye G , palme IB *et al* ; sputum concerns improves diagnosis of TB in setting with a high prevalence of HIV .
6. Bruchfeld j , aderaye G , palme IB *et al* :evaluation of outpatients with suspected pulmonary TB in a high prevalence setting in ethiopia : clinical , diagnostic and epidemiological characteristics . Scand j infect DIS .2002;34:331-337
7. Butt AA , Michaels S, kissenger P *et al* : the association of serum lactate dehydrogenase level with selected opportunistic infections and HIV progression . Int J Infect Dis 2002 : 178-181 .
8. Capley SJ, Well AU , Rubens MD , Gary Lee YC *et al* : asbestosis and IPF : comparision of the section ct features . radiology 2003; 229 ; 731-736.
9. Centres for the disease control and prevention: 1993 revised classification system for HIV infection and expanded surveillance case definition for AIDS among adolescents and adults. JAMA 1993;269:729- 730
10. Cluzer P , Bernadac P *et al* ; pulmonary corticomedullary system . CT finding . J comput Assist tomograph . 1991 :158:938-942 .
11. Daley CL *et al* ; bacterial pneumonis in HIV infected patients . semin respire infect.1993; 8;104 – 115.
12. Darcy D , Marciniuk w , tom martin , Vernon H . hoeppe *et al* : detection of pulmonary TB in patients with a normal chest radiograph .
13. D Ariezo p , gliampama E lavecchia MA *et al*; role of HRCT identification of atypical pulmonary myobacteriosis . radiol med 2002 ;1(3) :158-70

14. Diaz PT, wevers MD, patch E *et al* : respiratory symptoms among HIV seropositive individuals . chest .2003;123:1977-1982
15. Diehl SJ, lehmann KJ, thienel F *et al* : value of HRCT of the lungs in acute pulmonary symptoms of patients with HIV infections .Rofo. 1997;167 :227-33.
16. Dohn MN, white ML, vigdorth EM *et al* : geographic clustering of pneumocystis carini pneumonia with HIV infection . AM J Respir crit care med 2000;162:1617:-1621
17. Generux GP *et al*; fleshiner texture: CT of diffuse lung disease. J thoracic imaging 1989; 4:50-87.
18. Gold JA, Rom WN, harkin TJ :significance of abnormal chest radiographic findings in a patient with HIV -1 infection without respiratory symptoms . Chest 121:1472-1477.
19. Golden JA, Hollander H, stulbarg MS *et al* : bronchoalveolar lavage as the exclusive diagnostic modality for pneumocystis carini pneumonia : a prospective study among patients with acquired immune deficiency syndrome . Chest.1986; 90:18-22
20. Greenberg SD, frager D, Suster B *et al* : active pulmonary tuberculosis in patients with AIDS ; Spectrum of radiographic findings [including a normal appearance]. Radiology.1994; 193:115-119

Source of Support: Nil

Conflict of Interest: None