

## Sebaceous lymphadenoma of the parotid gland-a case report of infrequently encountered tumor

Nupur Rastogi\*

Department of Pathology, Government Medical College, Kota, Rajasthan, India

Received: 20-06-2017 / Revised: 28-06-2017 / Accepted: 05-07-2017

### ABSTRACT

Sebaceous lymphadenoma is a rare benign salivary gland tumor of uncertain histogenesis. In this present case report, a 41 year old female presented with swelling of left tail of parotid gland since 3 months. Fine needle aspiration cytology was done followed by histopathological confirmation. Prognosis is excellent following complete surgical excision of the tumor.

**Keywords:** Parotid, benign lesion, sebaceous lymphadenoma.

### Introduction

Sebaceous lymphadenoma of salivary glands has a very rare incidence [1]. It is a benign tumor constituting 0.196 % of all adenomas of the parotid gland [2]. It has uncertain histogenesis [3]. Fine needle aspiration cytology confirmed by histopathology establishes the diagnosis. The tumor has a benign course.

### Case report

A female aged 41 years presented in cytology OPD for fine needle aspiration cytology examination. She had a 2x2 cm nodular swelling below left ear (tail of parotid gland). On clinical examination the swelling was firm, mobile, and not attached to the overlying skin.

Fine needle aspiration was done using 22 guage needle and sterile syringe without anaesthesia. Air dried smears were stained with MGG. The cytomorphology

revealed cohesive clusters of epithelial cells, some demonstrating cytoplasmic vacuolization of sebocytes, surrounded by basaloid cells. These cells were admixed with lymphocytes. No mitosis or cellular pleomorphism was seen. The cytomorphological findings suggested a diagnosis of Sebaceous Lymphadenoma.( Fig 1 &2)

Biopsy was done to confirm the diagnosis. Grossly the tumor was well defined measuring 2x2 cm. Cut section was solid, homogenous. The histological features on H&E stain showed proliferating islands of epithelium with sebaceous glandular differentiation in a lymphocytic background. The tumor was well defined with no invasion in surrounding normal salivary tissue. There were scattered cystic ducts like structures composed of flattened epithelium. (Fig 3-5)

\*Correspondence

**Dr. Nupur Rastogi**

Department of pathology,  
Government Medical college, Kota, Rajasthan, India

E Mail: [nupurkota123@gmail.com](mailto:nupurkota123@gmail.com)

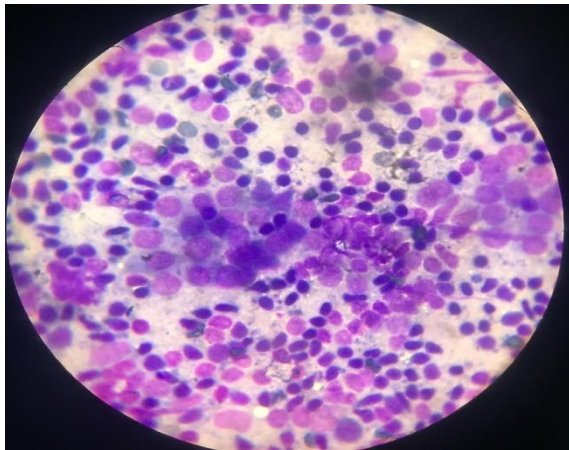


Fig 1: Cytology, MGG stain,40X, Epithelial cells

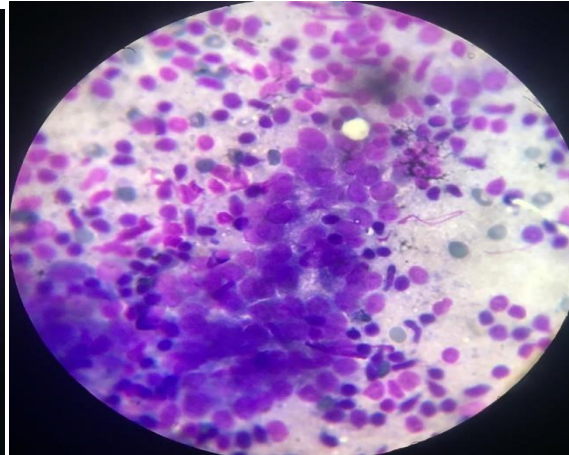


Fig 2: Cytology, MGGstain, 40X admixed with lymphocytes

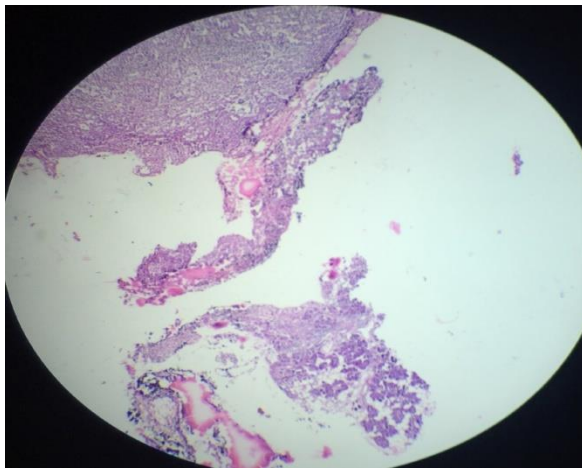


Fig 3:Biopsy,H& E , 10X, Section showing well defined tumour with surrounding normal salivary tissue

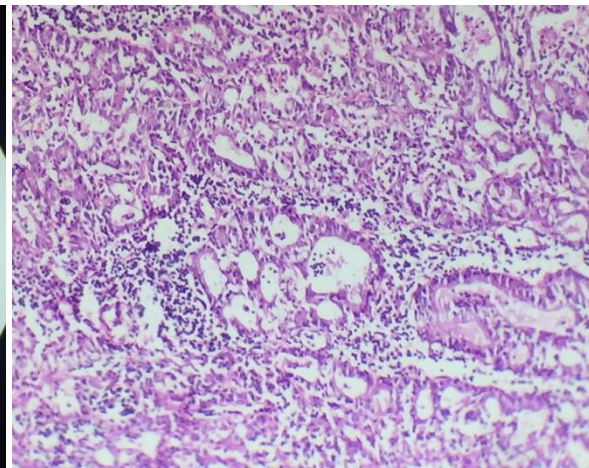
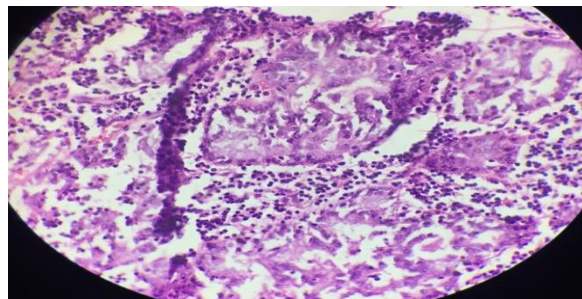


Fig 4: BiopsyH&E,40X,Section showing proliferating islands of epithelium with tissue lymphocytic background



**Fig 5: Biopsy, H & E,40X, Sebaceous differentiation with lymphocytes in background.**

This was distinguished from its other histological mimics like Warthin's tumor, Mucoepidermoid carcinoma, sebaceous lymphadenocarcinoma and sebaceous lymphoma without sebaceous differentiation. Considering all the differential diagnosis, a final diagnosis of Sebaceous lymphadenoma was made.

## Discussion

Sebaceous lymphadenoma is rare, benign neoplasm. It was first described by Rawson et al in 1950 [4] and then named by McGavran et al in 1959 [5]. Approximately 90% of these lesions are located in the parotid or periparotid lymph nodes [6] with a report of 1 case occurring in the midline of maxilla [7]. It can occur synchronously with other salivary gland tumors like Warthin's tumor [8], acinic cell carcinoma [9], pleomorphic adenoma, oncocytoma, basal cell adenomas [10]. The majority of sebaceous lymphadenomas occur in age group 25-89 years and have no sex predilection. Sebaceous lymphadenoma needs to be differentiated from low grade mucoepidermoid carcinoma as it is the most common primary malignancy in adults and children [11]. In sebaceous lymphadenoma, there is very little mucin seen within ductal cells or in ductal lumen unlike mucoepidermoid carcinoma where mucin pools surround the glandular cells [8]. Further lymphoid background dominates in sebaceous lymphadenoma. Further, it has to be differentiated from sebaceous adenoma and sebaceous carcinoma where there is more cellular pleomorphism with lack of lymphoid stromal background [6,8]. Other differential diagnosis are acinic cell carcinoma, epithelial myoepithelial carcinoma where these tumors lack lymphoid stroma. Metastatic carcinomas of intraparotid lymph node are important differential diagnosis. These are highly vascular with lack of cohesive epithelial clusters as seen in sebaceous lymphadenoma. The other differential diagnoses are sebaceous lymphadenocarcinoma, sebaceous lymphoma, papillary cystadenoma lymphomatosum [12].

## Conclusion

Sebaceous lymphadenoma is a rare benign salivary gland neoplasm that can be accurately diagnosed on Fine needle aspiration cytology and confirmed by histopathological examination. Complete excision of the tumor renders an excellent prognosis. Thus FNAC is an efficient, safe, economic means of diagnosis.

**Source of Support: Nil**

**Conflict of Interest: Nil**

## References

1. A. Mishra, K. Tripathi, L. Mohanty, M. Nayak, Sebaceous lymphadenoma of the parotid gland, 2011;54(1): 131-132.
2. Kuhn U, Kohler HH, Jecker P. Rare tumors of the parotid gland. Lymphadenoma of a sebaceous gland and extracranial metastases from glioblastoma. HNO 2003;51:417-20
3. Shukla M, Panicker S, Synchronous sebaceous lymphadenoma with squamous cell carcinoma- case report. World J Surg Oncol 2003;1:30
4. Rawson AJ, Horn RC: Sebaceous glands and sebaceous gland- containing tumors of the parotid gland. Surgery 1950; 27:93-101
5. McGavran MH, Bauer WC, Ackerman LV: Sebaceous lymphadenoma of the parotid salivary gland. Cancer 1960; 11:85-1187
6. Ellis GL, Auclair PL: Tumors of the salivary glands. In Atlas of Tumor Pathology. Third series, fascicle 17, Washington DC, Armed Forces Institute of Pathology, 1996
7. Kurokawa H, Tomoyuki M, Fukuyama H, Kajiyama M: Sebaceous lymphadenoma in the midline of the maxilla: report of case. J Oral Maxillofac Surg 1999; 57: 1461-1463
8. Gnepp DR, Brannon R: Sebaceous neoplasms of salivary gland origin: Report of 21 cases. Cancer 1984; 53:2155-2170.
9. Mayorga M, Fernandez N, Val-Bernal JF: Synchronous ipsilateral sebaceous lymphadenoma and acinic cell adenocarcinoma of the parotid gland. Oral Surg Oral Med Oral Pathol Oral Radiol Endod 1999;88: 593-596
10. Majeed M, Murray B, Hume W, Makura Z. Sebaceous lymphadenoma of the parotid gland. Dentomaxillofac Radiol 2008; 37:300-4.
11. DeMay R: Salivary glands in the art and science of cytopathology: Aspiration Cytology. Chicago, ASCP Press, 1996, pp678-679
12. Rund CR, Spies JA. A neck mass in a 57 year old man. Arch Path Lab Med 2004; 129: 171-2.