

## Furcation invasion- a literature review on its treatment modalities

Deepti Gattani<sup>1</sup>, Akhilesh Shewale<sup>2\*</sup>, Shweta Patnaik<sup>3</sup>

<sup>1</sup>HOD & Professor, Department of Periodontology, Swargiya Dadasaheb Kalmegh Smruti Dental College & Hospital Nagpur, Maharashtra, India

<sup>2</sup>Lecturer, Department of Periodontology, Swargiya Dadasaheb Kalmegh Smruti Dental College & Hospital Nagpur, Maharashtra, India

<sup>3</sup>PG student, Department of Periodontology, SDKS Dental college & Hospital, Nagpur, Maharashtra, India

### ABSTRACT

The pathologic resorption of bone in the anatomic area of a multirrooted tooth where the roots diverge is furcation invasion. Literature review on its treatment modalities is discussed in detail in this paper.

**Key Words:** Furcation, invasion, literature

### Introduction

A furcation invasion or lesion has been defined by the American Academy of Periodontology as 'the pathologic resorption of bone in the anatomic area of a multirrooted tooth where the roots diverge'. The progression of chronic inflammation during periodontitis may affect the bifurcation or trifurcation of multirrooted teeth. The furcation area has a complex anatomic morphology, which makes it difficult, if not impossible in some instances, to debride this area properly during routine periodontal instrumentation, as well as to clean it during routine home-care practices, when the root surfaces have been colonized by the subgingival biofilm. Furcation involvement is therefore an important complication in the progression of periodontitis and is a risk factor for progression of further attachment loss and, at the same time, reduces the efficacy of periodontal therapy. Different strategies can be used to deal with the furcation involvement problem. On the one hand, the furcation, and thereby the furcation involvement, may be eliminated. This can be achieved by elimination of the involved root (i.e. root resective therapy).

There are controversial reports in the scientific literature regarding the long-term results of these respective treatment modalities. On the other hand, periodontal tissues that have been destroyed by periodontitis can be regenerated, thereby decreasing the lesion. Regenerative periodontal therapy could be a means for dealing with advanced furcation involvement (Class II and Class III). The following article is an attempt to review various such treatment modalities [1].

### Prevalence and Distribution

**Tal (1982):** Furcation involvement 85% of 100 pts (untreated south Africans) FI increases with age, 1st molars most common.

**Tal (1982):** Correlation between depth of furcal defects and distance from the CEJ and alveolar crest, 5-6 mm suspect CL III

**Ross and Thompson (1980):** 615 molars from 72 perio pts, 90% FI in maxilla and 35% in mandibular, only 22% of maxillary furcations could be diagnosed solely with X-rays.

**Larato (1970):** 305 Mexican dry skulls, Furcation involvement increases with age, 1st molars most common (maxillary more than Mandibular), buccal more than lingual/ palatal. Incidence related to length of time in mouth, decreases as more posterior except premolars.

**Svardstrom (1996)** Highest frequency of furcation involvement is the distal of Maxillary 1<sup>st</sup> molar (53%). Lowest frequency of furcation involvement is the mesial of the Maxillary 2<sup>nd</sup> molar (20%)

\*Correspondence

**Dr. Akhilesh Shewale**

Lecturer, Department of Periodontology, Swargiya Dadasaheb Kalmegh Smruti Dental College & Hospital Nagpur, Maharashtra, India

**Etiology**

**Kalkwarf& Reinhardt (1988)**

1. Anatomic factors: carious lesions, restorations, furcation morphology-width, shape, root trunk length
2. Enamel projections: role as contributing factor uncertain
3. Occlusal trauma: still may be controversial

**Waerhaug (1980):** Plaque is the main contributor, subgingival plaque even in areas where no supragingival plaque was evident, GI and PI do not reflect actual level of destruction of furcation, loss of attachment did not increase with increasing mobility.

**Contributing Factors to Furcation Involvement:**

**(1) Root Concavities**

**Bower (1979): Furcation root surface anatomy**

1. Maxillary 1st molar teeth
  - furcal aspect of root concave 94% MB, 31% DB, 17% P
  - Deepest concavity was in the MB root- mean concavity 0.3 mm
  - furcal aspects of buccal roots diverge toward the palate in 97%, divergence 22°
2. Mandibular 1st molar teeth
  - furcal aspect of root was concave 100% M, 99% D
  - deeper concavity on M root (0.7mm), D root (0.5mm)
  - concavity presence of more cementum

**Gher and Vernino (1980):** Maxillary 1st premolars - groove furcation side buccal root 78%, 1st Max molars concave facial side of MB, Mandibular have M and D concavities[2].

**(2) Cervical enamel projections**

**Masters and Hoskins (1964):**

**Wheeler (1968):** Furcation entrances, location from CEJ

CEP Mandibular 28.6%, maxillary 17%, 90% of Mandibular furcations associated with CEP's.

**Grade I** - CEP very slightly extending from CEJ

**Grade II** - CEP approaching furca

**Grade III** - CEP extending into furca

**Leib, Berdon, Sabes (1967):** CEP's: maxilla: I>III>II, Mandibular. I>II>III. No correlation between CEP presence and furca involvement. 22% maxillary molars and 25% mandibular molars, 4% are class 3s.

**Hou and Tsai (1987)**

1. CEP's in all molars 45.2%
2. CEP's in molars with furcation involvement 82.5%, Mandibular 1st molar most common (all other studies suggest CEP's more common in 2nd molars), 1st Maxillary, 2nd Mandibular, 2nd Maxillary
3. Chinese two times more prevalent than Caucasian population

**Swan and Hurt:**

Significant relationship between tooth surfaces with grade II and III furcations and CEP's,

(3) Accessory Pulp Canals

Gutman (1978): 28% in furcation region; 24% in furcation only

Lowman (1973): 59% Navy study treated periodontally 10-12 weeks after endodontic treatment

**Vertucci**46%

**Burch and Halen:** 76%

**(4) Bifurcation Ridges**

**Everett (1958):** bifurcation ridge is present 73% Mandibular 1st molars running Mesial to Distal at the midpoint of bifurcation

**(5) Root Trunk Length**

**(6) Width and Location of Furcation Entrance**

**Table 1:Furcation entrances, location from CEJ**

Max 1st molar	Man 1st molar
mesial 3mm	buccal 3mm
buccal 4mm	lingual 4mm
distal 5mm	

**Bower (1979):**

1. Mean M-D width maxillary 1st molars was 7.9 mm, Mandibular 1st molars was 9.2 mm
2. 81% of all furcations have entrance diameter 1.0 mm, 58% the diameter was 0.75mm or less
3. Extremely low correlation between M-D width of tooth and furcation entrance diameter
4. Blade face width of the curesttes tested were within 0.75 mm to 1.10 mm .

**Hou and Tsai (1994):** Furcation entrance means

**Table 2: Furcation entrance means**

	Max 1st molar	Max 2nd molar		Man 1st molar	Man 2nd molar
<b>Buccal</b>	0.74mm	.63mm	<b>Buccal</b>	.88mm	.73mm
<b>Mesial</b>	1.04mm	.90mm	<b>Lingual</b>	.81mm	.71mm
<b>Distal</b>	0.99mm	.67mm			

**Diagnosis: Zappa et al (1993):** Using Ramfjord and Hamp indexes, Overestimation of furcation defects

**Mealey et al (1994):** Bone sounding with anesthesia significantly improves the diagnostic accuracy of furcation invasions as compared to standard probing techniques. (Vertical and horizontal) If no anesthesia, tend to underestimate by 1-1.5 mm.

**Kalkwarf (1988):** Diagnosis not complete until surgical access[3].

#### Detection of Furcation Invasions

The furcation invasion is detected by passing a curved instrument (pigtail explorer, worn-out curet, Nabers 2N probe) into the sulcus or pocket on the facial and lingua/palatal of all molars and from the mesial or distal of maxillary 1st premolars of the furcation. The objective is to determine if the separation between roots can be felt and, if so, to what degree. A curved instrument is particularly valuable in the detection of distopalatal or mesiopalatal furcations.

If detected, the severity should be recorded in the patient's chart. Useful symbols on chartings are **Class I =  $\wedge$** , **Class II =  $\Delta$** , and **Class III =  $\blacktriangle$** . A helpful modification to this system is to estimate the horizontal component of a Class II furcation in mm (e.g.,  $\Delta$  3). For example, Class II furcations on the mesial, distal and buccal of #14, are recorded as follows:

**Fig 1: Mesial, buccal, distal, palatal furcations**

**Treatment of furcation invasion:** The treatment or correction of a furcation invasion involves one or more of the following procedures: The selection of a procedure is dependent on several factors, including the severity of furcation invasion, amount of remaining bone support, status of abutment teeth, and strategic importance of the involved tooth. Generally, the more severe the invasion, the more involved the therapy.

1. Root Curettage
2. Odontoplasty
3. Osteoplasty
4. Root Resection
5. Hemisection
6. Tunneling
7. Regeneration

Classification of furcation involvement (Hamp, Nyman, Lindhe <sup>33</sup> )	Degree I	Degree II	Degree III
	Horizontal Osseous defect ≤ 3 mm but within 1/3 of the root width	Horizontal Osseous defect > 3 mm beyond 1/3 of root width but does not extend to the whole furcation area	Through and through
Concept of treatment of furcation involvement (Kalkwarf & Reinhardt, <sup>34</sup> partially modified)			
Maintain furcation	Scaling, root planing Flap curettage	Flap curettage	Flap curettage
Increase access to furcation	Apically positioned flap Odontoplasty Osteoplasty, ostectomy		
Removal of furcation		Root resection Hemisection	Root resection Hemisection
Closure of furcation with new attachment		Flap curettage with barrier membrane (GTR)	Flap curettage with barrier membrane (GTR) Strategic extraction

Fig 2: Classification and concept of treatment for furcations

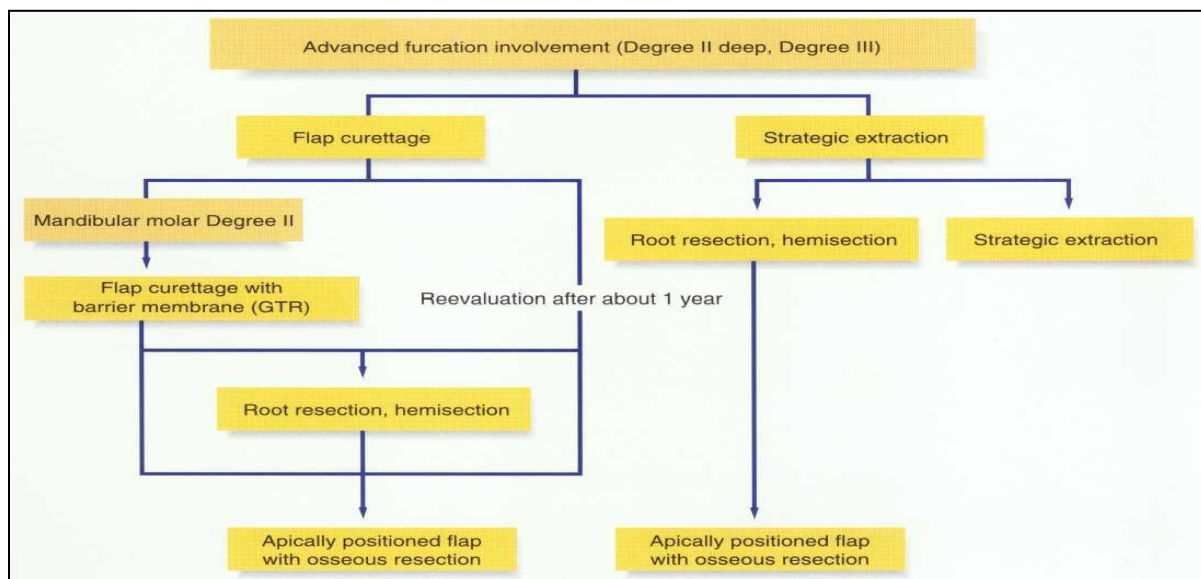


Fig 3: Advanced furcation involvement

**1. Root Curettage**

Incipient furcation invasions (Class I) often require nothing more than periodic rounds of root curettage in order to control inflammation. Generally, this practice works well when the interradicular fluting is broad and access is not a problem.

**Non-surgical therapy**

**Loos et al. (1989):** In sites of > 7 mm regressed after initial treatment, Overall 25% of molar furcation sites demonstrated loss of attachment compared to 7% for non-molar sites and 10% of molar flat-surface sites.

**Badersten:** Non-surgical therapy works, but in non-molar teeth only.

**Nordland (1987):** Furcations with initial pocket depth > 4mm had poorer response to non-surg therapy verses flat molar and non-molar sites. 0.5mm loss in 24 months

**Leon and Vogel (1987)** Compared hand and ultrasonic scaling in furcations

Class I No difference between modalities


Class II and III ultrasonic scaler better.

**Parashis (1993)** Calculus removal in furcations best with open scaling and rotary diamonds

**Bower (1979)** Width of furcation entrance is too narrow for most scalers

**2. Odontoplasty**

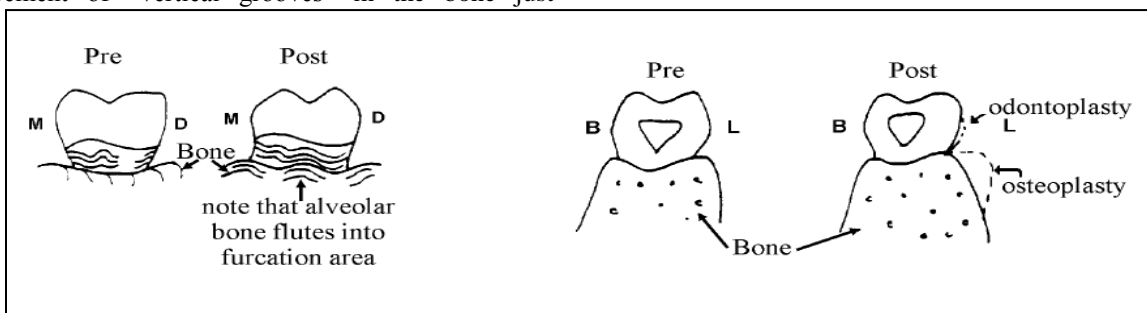
This term means, “The reshaping of the tooth.” With respect to furcation invasions, it means the widening of the furcal area in a buccolingual or mesiodistal as well as apicocoronal direction with a high-speed diamond. The net effect is to widen the inter-radicular area and to remove or reshape the horizontal component of the furcation invasion. The furcation is thus made more accessible for oral hygiene efforts. The initial reshaping is done with round diamonds and is refined with curets. This procedure is really limited to Class I and shallow Class II furcation invasions. The deeper the invasion, the more reshaping that is required, and thus the more tooth structure that must be removed. Such removal increases the likelihood of dentinal sensitivity, which can be so severe that root canal therapy is required[4,5].



**Fig 4:X-section at the level of CEJ of #18**

**3. Osteoplasty:** If the fluting is narrow or there is restricted access to the furcation, osteoplasty/odontoplasty procedures may be necessary. The tooth and alveolar bone in the furcation area are reshaped. The elimination of bony ledges and the placement of “vertical grooves” in the bone just

coronal to the furcation make the contours more gradual in an apical-coronal direction, which improves access for home care devices and curets. This technique is generally employed as part of a segment of periodontal surgery, and is not often used alone.



**Fig 5: Pre and post odontoplasty and osteoplasty**

#### 4. Root Resection

Root resections (amputations) are utilized when the furcation invasion is too advanced to be corrected by the previous techniques. Access to the furcation can be gained by removing one or more of the affected roots. A flap is reflected to expose the underlying bone. The bony plate covering the involved root is removed to about 2/3rds of its length. A bur is used to cut through the root to be removed. This cut is apical to the

opening of the furcation. Once resected, the root is extracted. The remaining stump is contoured to smooth out any sharp angles and to remove any undercuts. This is critical so the restorative dentist can prepare the tooth for the eventual crown. If endodontic therapy has not been previously performed, ZOE is placed into the opening to the canal.

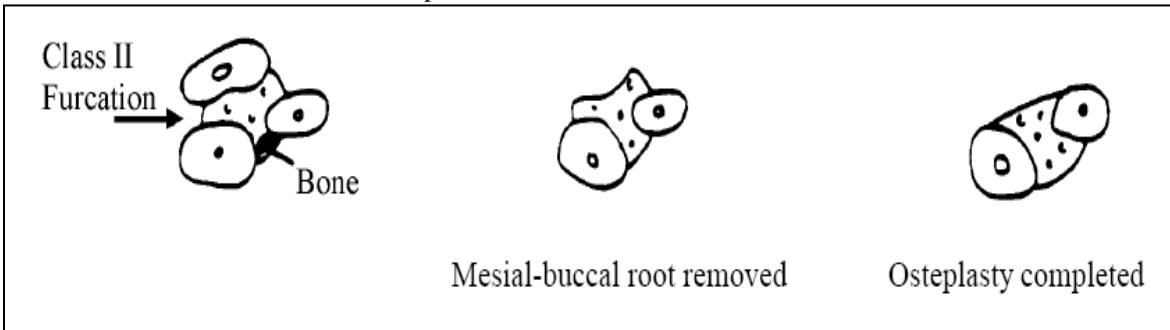


Fig 6: X-Sections of upper molar just apical to furcation

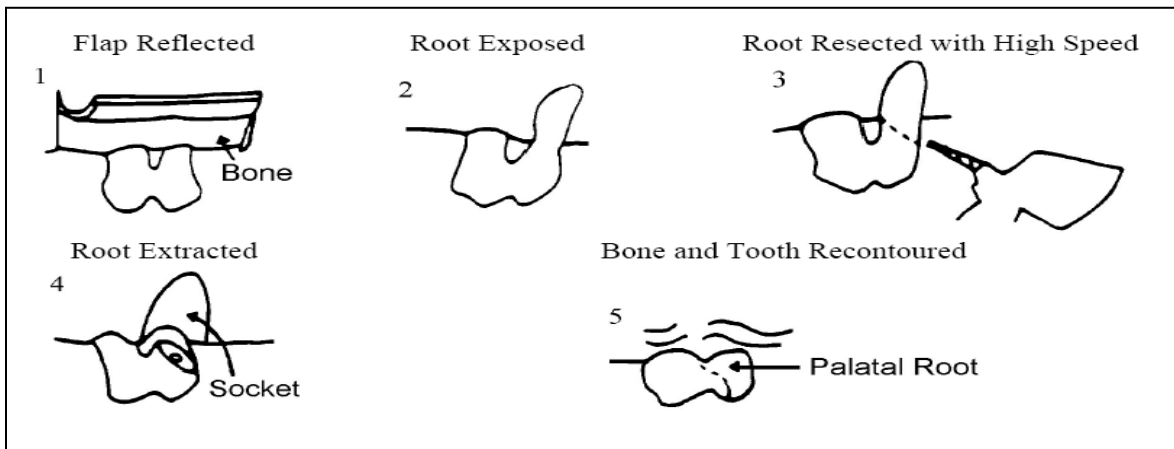


Fig 7: Different phases of root extraction

#### Indications & Contraindications to Root Resections (Basaraba,1969)

##### Indications:

1. Uncorrected bone loss involving one root of a mandibular molar, one or two buccal roots or a palatal root of a maxillary molar
2. Furcation invasion such that odontoplasty is not indicated (greater than Class I).
3. When root proximity prevents proper maintenance.

4. When osseous recontouring (ostectomy) would cause the exposure of a furcation.
5. To improve the prognosis of teeth within a fixed bridge
6. Fracture of a tooth or root
7. Failure of endodontic therapy in one canal and correction or retreatment of this canal is not possible
8. When recession exposing the entire length of a root cannot be corrected with mucogingival procedures.

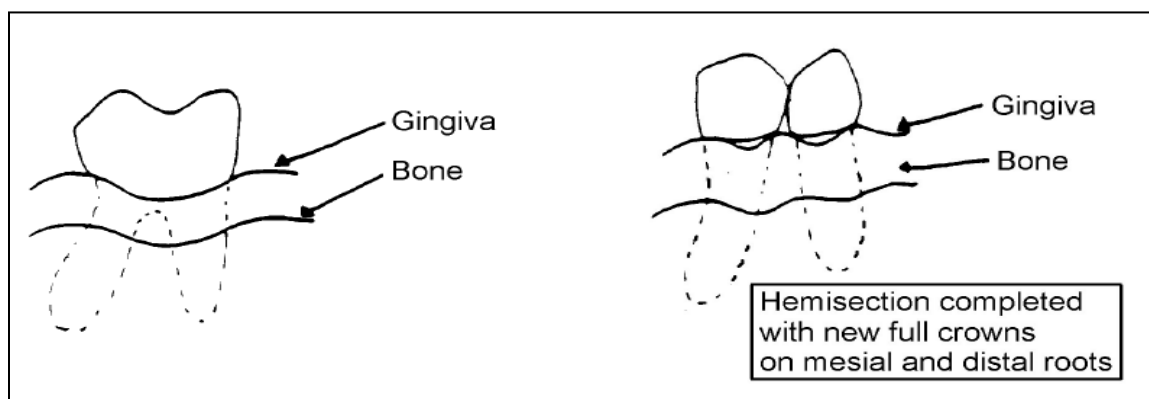
### Contraindications

1. RCT cannot be done on the remaining roots, e.g. partly calcified canal or fused roots
2. Bone loss around the remaining roots is too severe to be corrected via periodontal procedures.
3. Class I furcation invasion.

### 5. Hemisection

In a hemisection the tooth is cut in half. The technique is used virtually exclusively on mandibular molars to treat Class II or III furcation invasions. The tooth is sectioned from buccal to lingual, parallel to a line joining the buccal and lingual furcas. In contrast to root amputations, extraction of one of the sections does not necessarily need to be performed. For example, if

No. 19 has a Class III furcal invasion and each root still has adequate bone support, the tooth can be divided in half and each half treated as a separate “premolar”. Access to the furcation is now gained though the “new” embrasure area. A hemisection often will be followed by the extraction of one of the sectioned halves. This is done primarily when the severe attachment loss is restricted to one root, the other root can be treated, and there is no other stable distal abutment. A bur (high-speed) is used to cut through the coronal portion of the tooth separating it into two halves. It is advisable to make the coronal cut prior to flap reflection to minimize the amount of tooth structure and restorative material that gets into the surgical site[6,7].



**Fig 8: Hemisection completed with new full crowns**

Root amputations or hemisections almost always result in irreversible pulpal damage that demands endodontic therapy. Ideally the endo is done first which ensures patient comfort. Sometimes the decision to do a root resection cannot be made until flaps have been reflected and the periodontal status has been carefully assessed. The RCT must be delayed until after the resection. Regardless of the sequence, consultation with both endodontist and periodontist is required to ensure both aspects of the treatment can be performed. Thus the strategic importance of the involved tooth should be carefully assessed prior to commencing either a root amputation or hemisection. Is it better to extract the tooth and replace it with a FPD or an implant or is it better to proceed with the root resection? The procedures involved in a hemisection are expensive. They include the cost of the surgery, root canal therapy on the remaining root, and a crown. Furthermore after the removal of half of a mandibular molar an edentulous space is created that may require the construction of a FPD. However, if the involved tooth is a 1st molar and the terminal tooth in the arch,

its retention may be far more critical than if it were a 1st molar with adjacent solid 2nd molar and 2nd premolar. The principles of crown preparation remain whether or not a tooth has had a root amputation. There must be sufficient reduction for “draw” without compromising retention, and the preparation must terminate on solid tooth structure. The completed prep looks quite different from a typical crown prep. Undercuts that remain in the area of the root amputation must be removed. A full occlusal table would be waxed in with a gradual occlusal-apical contour in the area of the root amp so that the crown is not overcontoured. Langer et al, made a 10-year evaluation of root resections. Of 100 teeth so treated, 38 had failed by the end of 10 years. Interestingly although the primary reason for performing the root resections was to treat periodontal lesions, most of the failures (28 of 38) were due to endodontic or restorative problems such as root fractures, cemental washouts, caries, and recurrent periapical pathoses. Mandibular molars failed twice as often as did

maxillary molars. On a more positive note 62% of the cases did last a decade.

**Root Amputations:** Consider implants, may have better long term success

**Langer et al (1981):** 10yr, 100pts, results are as follows for resected teeth: 38% of resected teeth failed by 10 yr. mark (62% success rate), 15.8 % in 5yr.

Of the failures:

1. 47% (greatest number of teeth) failed due to root fractures
2. 26.3 failed to progression of periodontal disease, most were maxillary molars
3. 18.4% failed to endodontic procedures
4. 7.9% failed due to cement washout

**Erpenstein (1983):** 3 yr. hemisections, 6/34 failed due to endodontics, 1 failed due to periodontal reasons. Suggests favorable prognosis for hemisections, but these resections were sometimes done without surgical access and no osseous recontouring was performed.

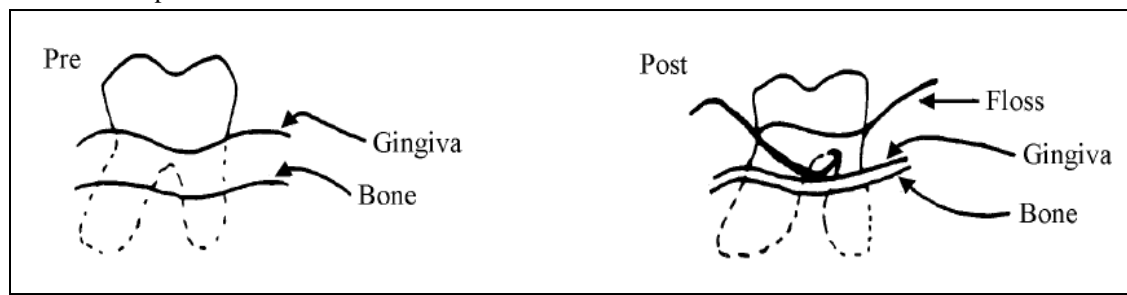
**Carnevale et al (1991):** 500 teeth with either root amps or hemisections. Overall 5.7% failures, highest being caries and root fractures, 97.6% of these teeth were treated for periodontal reasons, only 0.6% had recurrence of periodontal breakdown

**Buhler (1994):** 337 cases, 7 yr. period of hemisection, reported failure rate of 13.1%.

**Klavan (1975):** Mean 38 month follow-up study of primarily DB root amps. Only 3/33 teeth showed an increase in mobility after the root amp. The removal of one of the roots of a maxillary molar does not increase the mobility of the tooth in normal function or contribute to increased PD. Splinting does not seem to be necessary.

#### 6. Tunneling

The “tunneling” procedure has been used in Class III furcation inversions. A flap is reflected, osteotomy and osteoplasty usually are required, and the flap is sutured in an apical position exposing the furcation to the oral cavity so that it is accessible for oral hygiene measures. This is generally limited to molar teeth with well-separated roots. Roots in close proximity are not good candidates because of the difficulty in obtaining access for plaque control. The tunneling procedure is not done frequently. Caries may develop because of the difficulty in removing plaque from the furcal “roof” which often is concave. Interproximal brushes dipped in fluoride and irrigation using a Mono-Jet syringe and chlorhexidine may help to slow caries activity.



**Fig 9: Tunneling**

**Little (1995):** 18 pts with 5 maxillary and 13 mandibular furcations treated by tunneling. Adjacent teeth were used to evaluate bone loss. After 5 yr., 3/18 had developed root caries. No difference seen in CAL or bone loss when compared to adjacent teeth.

**Hellden, Steffensen et al (1989):** 149 teeth with Grade III furcations at 3 yrs, 75% caries free.

**Hamp, Nyman, Lindhe (1975):** Treatment of teeth with furcations revealed the following 5 yr. results:

1. 44% of the teeth were extracted during initial treatment
2. 50% of the remaining teeth received root resections, one root preserved 64% of the time, none of the teeth were lost in 5 yrs
3. Tunneling procedure had root caries 4/7.

#### 7. Regeneration

Regeneration procedures designed to recreate lost periodontal attachment have not been particularly rewarding especially in furcation invasions. Recent interest has focused on “guided tissue regeneration” in the treatment of Class II & III defects. In this technique, full-thickness flaps are reflected, the areas are thoroughly debrided, and a synthetic membrane or other material is placed over the bony defect. The actual defect may or may not be filled with freeze-dried bone prior to the placement of the membrane. The theory behind this technique is that regeneration of the attachment apparatus may occur if cells from the PDL are allowed to repopulate the affected root surfaces. The membrane serves as a barrier and excludes gingival connective and epithelium tissues from the



healing process. It is hoped that a true new attachment of bone, ligament, and cementum will result.

➤ **GTR in Furcations**

**Gantes (1991):** Class 3 furcations, citric acid and coronally positioned flaps with moderate results.

**Lu (1992):** Complete circumferential adaptation of the membrane to the root is not possible, gaps will remain. Occlusal border should be placed 1-2mm below CEJ. GTR success may be more from clot stabilization than from epithelial exclusion.

**Pontoriero et al (1988):** GTR in class II furcations, 14/21 complete closure, 5/21 had residual of < 1 mm. 90% closure of Class II's with membrane, OFD 2/21 completely closed, No reentries. GTR better than OFD in Class II furcas.

**Pontoriero (1989):** Class III, 8/21 closure with GTR, control 0/21, no re-entry, clinical probing depth only.

**Pontoriero (1995)** Buccalfurcations more predictable than interproximal furcas, GTR doesn't work in class III furcas.

**Lindhe et al (1995):** Flap management and bioresorbable membranes in class III molar furcations in dogs:

-Large furcation defects can be treated provided soft tissue flaps covering membranes prevented from recession

-Resolute equally as effective as e-PTFE.

**Anderegg et al (1991):** 15 pts, molar furcas, GTR alone vs. GTR and DFDBA (BETTER), 6 mo re-entry, combined more fill, more PD reduction, greater attach gain both horizontal and vertical.

**Mellonig (1991):** IJPRD: Class 2s, membrane better than OFD, improved HOPA/VOPA, GTR will improve clinical results, rarely complete closure.

**Mellonig (1994):** 13 pts with grade II furcas. Comparison of ePTFE vs. debridement-6 month re-entry.ePTFE sites showed more PDR, ALG, as well as recession in man II defects. There was no difference between the 2 txs in max grade II furcas.

**Anderegg (1995):** Gingival thickness in GTR. 37 pts with grade I or II max or man furcas were txd with GTR. Pts with ≤1mm of gingival thickness had 2.1mm of recession at 6 mos. postop. Pts with >1mm gingival thickness only had 0.6mm recession. *Less recession with thicker tissues.*

**Lekovic and Kenney (1989):** class II furcations, e-PTFE vs. OFD, test site showed PD reduction, gain in attachment levels of 2.86mm, vs. controls which didn't change from preoperative levels.

**Nygaard Ostby (1996)** GTR vs. OFD. GTR has no significant advantage over OFD. No grafts were used.

**Metzler and Mellonig (1991):** GTR vs. OFD in Maxillary II furcations, 6 mo re-entry, overall results inconsistent and unpredictable, recession 0.7mm.

➤ **ePTFE + GRAFT in furcations**

**Lekovic et al (1990): grade II furcations** PTFE+HA vs. PTFE alone, 30 defects, PTFE+HA had 2.9 mm attach gain vs. PTFE alone of 2.4 mm. PTFE+HA had greater vertical/horizontal bone gain and less recession.

**McClain and Schallhorn(1993):GTR + GRAFT =Long term stability**

DFDBA + autog + GTR + C.A. = 4.0 mm mean clinical AGAIN, including furcation fill.5 yr. follow-up of GTR with and without CA root conditioning and composite grafts. Long term results enhanced with CA + graft, 5yr stability of CPAL. 93% stable with graft, 30% stable with membrane only..

**Garrett (1994):** Grade III man furcations treated with DFDBA alone or DFDBA + ePTFE. Both covered by CPF.. No benefit was seen with the use of ePTFE.

**Wallace (1994):** Grade II mandibular furcations treated with either ePTFE alone or ePTFE + DFDBA. 6 month re-entry showed similar results as far as recession, and reduction of horizontal defect depth were concerned. The ePTFE + DFDBA group showed greater vertical defect fill and greater PALG when compared to the ePTFE only group.

**Mellado(1995):**ePTFE with and without DFDBA more bone formed without DFDBA Anti-DFDBA study.

**Furcations - long term maintenance studies**

**Pearlman (1993):** 172 pts classified similar to Hirschfeld and Wasserman with similar breakdown of results. Finding was that even in the well maintained group, there were more molars lost with furcation involvement over those without involvement.

**Hirschfeld, Wasserman (1978):**

22 yr. maintenance study of 600 pts.

1. 31% of teeth with original furcation invasion were lost
2. Breakdown of teeth lost according to groups WM 19.3%, D 69.9%, ED 84.4%
3. Average overall tooth loss by patient groups WM 0.68, D 5.7, ED 13%
4. Order of tooth loss: Max 2nd, Max 1st, Mn 2nd, Mn 1<sup>st</sup>
5. 300 lost no teeth, 199 lost 1-3 teeth, 76 lost 4-9 teeth, 25 lost 10-23 teet
6. Mortality of teeth correlated more closely to case type rather than type of surgery
7. Periodontal disease is symmetrical

PATIENT PERCENTAGES: Well Maintained 83%, Downhill 12.6%, Extreme Downhill 4.2%

**Ross and Thompson (1978):**100 pts treated with 387 furcations,. Conservative treatment only OFD, no resection or osseous treatments, 5 yr. Minimum follow

up, 88% of teeth were functioning after 5-24 yrs, and radiographs were the only diagnostic tool of success. Maxillary Furcation involvement three times that of Mandibular. Maxillary furcations were detected most frequently by radiographs, Mandibular furcations detected most frequently by clinical exam.

**McFall (1982):** 100pts in maintenance for 15 yrs. 57% of teeth with initial furcation involvement were eventually lost with 25% being lost in the well maintained category. Avg. overall tooth loss:

- Well Maintained - 0.68
- Downhill - 6.7,
- Extremely Downhill - 14.4

**Goldman, Ross (1986)**

211 pts, 15-34 yrs with maintenance.

1. Furcation teeth lost Well Maintained 16.9%, Downhill 66%, Extremely Downhill 93%
2. Avg. overall tooth loss: Well Maintained 1.0, Downhill 5.8, Extremely Downhill 14.2

**Becker studies (1989):** No therapy group: 31% furcations became involved at second exam 5 yr. 22% furcations got worse at 5 yrs.

Therapy w/maintenance: 22% furcations became involved at second exam 5 yr. 12% furcations got worse at 5 yrs.

**Kalkwarf, Kaldahl, Patil (1988)**

82 pts, 1394 furcations, teeth were treated with CS, RP, MWF, F/O teeth were extracted, resected, hemisection, if bone loss past apex or bony architecture not corrected.

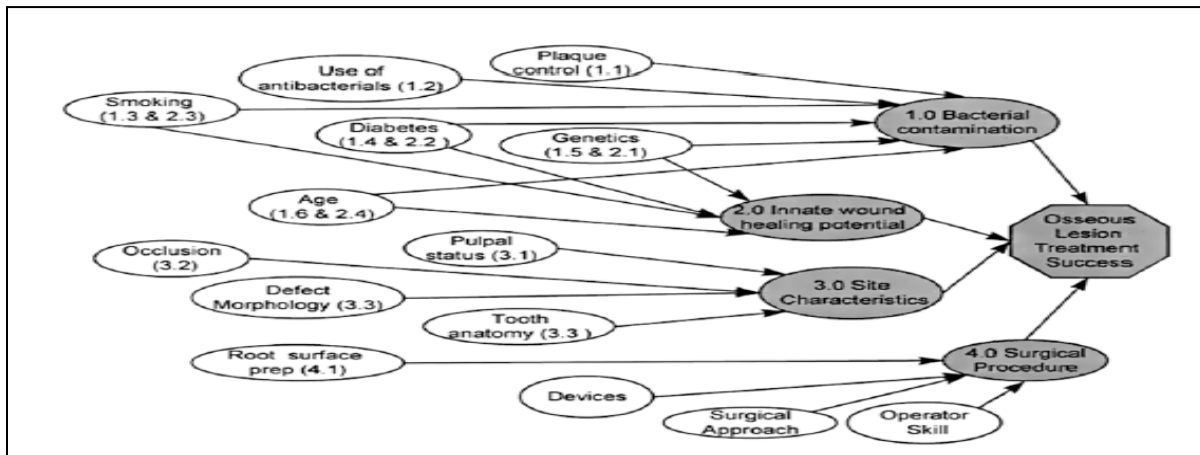
- 2 yr. - F/O had less breakdown than other treatment, but several more teeth taken out in the group
- 5 yr. - Less breakdown with F/O (4.1%) although overall the other therapies haven't caught up with total extractions

**BL:** FO does better if one can create a positive architecture otherwise the MWF or OFD may be the better treatment as far as tooth loss goes

**Wang (1994):** 24 pts 8yr study with 3 month recalls. Molars with initial mobility showed greater LOA than ones without mobility. Molars with furcation involvement also showed greater LOA over this time period than molars without furcal involvement[8,9].

**Summary of the above studies stresses the importance of maintenance in pts with FI and that the majority of tooth loss occurs in a minority of pts.**

**Factors affecting the outcome of therapy**



**Fig 10: Factors affecting the outcome of therapy**

Biological phenomena that involve complex interactions among many factors are often explored in a sequential series of studies, and therapies for osseous defects have followed that path. Guided tissue regeneration studies are used as an example.

✓ Bacterial contamination:

- ✓ Inadequate plaque control, or the presence of specific bacteria, have been associated with less favorable clinical outcomes following regenerative therapy
- ✓ Antibacterial therapies offer some promise, but interpretation of the
  - clinical data is complicated

- ✓ Smoking influences the bacterial composition of the plaque
- ✓ Poorly controlled diabetes influences the control of microbial infections and the severity of periodontitis but has no clear influence on the bacterial composition of dental plaque
- ✓ Genetic factors associated with different clinical types of periodontitis influence the plaque composition
- ✓ Aging alters resistance to microbial infections
- ✓ Innate wound-healing potential
- ✓ Genetic factors influence mediators of inflammation
- ✓ Diabetes influences wound repair and healing
- ✓ Aging influences specific components of the wound healing process
- ✓ Pulpal status has been associated with adverse periodontal wound healing under certain conditions
- ✓ A role for occlusion in the outcomes of regenerative procedures has not been established
- ✓ Defect morphology and tooth anatomy appear to influence the outcome of regenerative therapy
- ✓ Surgical procedure
- ✓ Root surface preparation [9].

### Conclusion

An evaluation of the scientific literature on the various therapies of furcation lesions warranted the following conclusions. An abundance of studies and several systematic reviews with meta-analyses have demonstrated efficacy of guided tissue regeneration therapy for the regenerative treatment of furcation defects. Guided tissue regeneration therapy generally results in significantly higher horizontal defect fill (i.e. horizontal probing attachment level and/or horizontal probing bone level gain) in Class II furcation involvement of mandibular and maxillary molars when

compared with open flap debridement. Although cell-based therapies have received considerable attention in regenerative medicine, their experimental evaluation in the treatment of periodontal furcation lesions is at a very early stage of development. In summary, the indications and the limitations for currently available treatment modalities for the regeneration of furcation defects seem well established. In the future, new regenerative treatment modalities are clearly needed to improve the predictability of complete resolution of furcation defects.

### References

1. Carranza's Clinical Periodontology, 10th edition
2. Text book of Clinical Periodontology, Lindhe, 2nd edition.
3. Cohen's Atlas of Cosmetic & Reconstructive Periodontal Surgery
4. Kevin G. Murphy .The role of resective periodontal surgery in the treatment of furcation defects. *Periodontology* 2000;22:154–168.
5. Garrett S. Periodontal regeneration around natural teeth. *Ann Periodontol* 1996; 1: 621-666
6. Muller HP, Eger T. Furcation diagnosis. *J. Clin. Periodontol* 1999; 26:485-498
7. Al-Shammari KF, Kazor CE, Wang HL. Molar root anatomy and management of furcation defects. *J. Clin Periodontology* 2001; 28; 730-740
8. Caffesse RG, Mota LF, Quin'ones CR, Morrison EC. Clinical comparison of resorbable and non-resorbable barriers for guided periodontal tissue regeneration. *J Clin. Periodontol* 1997; 24: 747-752.
9. Marcello Cattabriga. The conservative approach in the treatment of furcation lesions. *Periodontology* 2000;22: 133–153

**Source of Support:** Nil

**Conflict of Interest:** None