

# Metastatic malignant melanoma from an unknown primary presenting as an axillary mass

Saumil Garg, Sonam Sharma\*

Department of Pathology, Kalpana Chawla Government Medical College, Karnal, Haryana, India

## ABSTRACT

Malignant melanoma is a primary skin cancer, the incidence of which is rising at a faster rate than any other malignancy. Regional lymph nodes metastasis is seen in two-thirds of the patients of malignant melanoma. However, patients are also known to present with metastatic nodes in the absence of a known primary. The authors report a rare case of metastatic malignant melanoma from an unknown primary in a 62-year-old male who presented with an axillary mass.

**Key words:** Axillary mass, lymph node metastasis, melanoma, unknown primary

## INTRODUCTION

Malignant melanoma (MM) is one of the most belligerent tumor, arising from skin melanocytes. It has a propensity to metastasize early to different organs of the body, and hence, it can present with a variety of signs and symptoms, creating a diagnostic conundrum for the treating physicians.<sup>[1]</sup> Although most of the lesions of MM are classically pigmented, nevertheless amelanotic melanomas are also known.<sup>[2]</sup> Metastatic MM with an unknown primary is a rare lesion to occur, with only handful of cases reported in the literature.<sup>[1,3]</sup> We describe a rare case of metastatic MM from an unknown primary in a 62-year-old male who presented with an axillary mass as its sole manifestation and was diagnosed on the basis of cytology.

## CASE REPORT

A 62-year-old male presented in the surgical outpatient department with the complaints of a large right axillary mass for the past 1 month. His general as well as systemic examinations were within normal limits. On local examination, the axillary mass measured 5 cm × 4 cm in size. It was fixed, non-tender, firm in consistency, and the overlying skin was normal [Figure 1a and b]. On fine-needle aspiration cytology (FNAC) of the axillary mass, thick black-colored material was aspirated and smears were prepared which were subsequently stained with May-Grunwald-Giemsa stain. Microscopic examination revealed highly cellular FNAC smears with a predominance of round-to-oval pleomorphic cells which were mainly scattered singly. Individual cell had abundant cytoplasm and eccentrically placed hyperchromatic nuclei with prominent nucleoli. Dusty black-colored melanin pigment was also found in the cytoplasm of these cells and in the background. Few binucleated and spindle-shaped cells along with many dispersed macrophages and lymphoid series of cells in various stages of maturation were also evident [Figure 2a and b].

Based on these cytological findings, a diagnosis of metastatic MM to the right axillary lymph node was made. This triggered us to take a proper history and to do the clinical examination again in search for a primary MM lesion. On reexamination, an irregular scar mark was seen on his right arm [Figure 3a and b]. On further enquiring from the patient, he revealed that he had a blackish-brown-colored patch on his right arm for the past 2 years, but he was operated for it 6 months back at a private center, and presently, he has a scar mark at that site. However, no reports pertaining to it were available with him. The patient was advised for excision biopsy of the axillary mass and also for further metastatic work up. Unfortunately, he was lost to follow-up.

## DISCUSSION

Patients having cancers from an unknown primary site generally present with widespread metastasis along with constitutional signs and symptoms. Liver, lung, lymph nodes, and bones are the most common sites for metastasis. Therefore, identification and classification of such neoplasms should be carefully done for proper therapeutic intervention and prognostication.<sup>[1]</sup>

MM is a well-known rapidly progressive skin cancer and death in such cases results due to multiple organ metastasis. Metastasis from MM most often presents as cutaneous/subcutaneous nodules or as lymph node metastasis. A varying percentage of cases have simultaneous visceral metastasis at the time of diagnosis. Two factors responsible for the homing of melanoma cells to different sites are lymph flow and chemotaxis.<sup>[4]</sup> Therefore, an early detection of metastatic disease is essential as the diagnosis of such lesions directs the staging, treatment, and prognosis of this aggressive tumor.<sup>[5]</sup>

The incidence of metastatic MM with an unknown primary has been reported to be 2–10% in various studies.<sup>[3,6,7]</sup> Its incidence

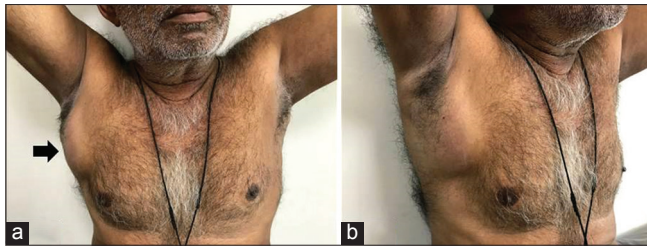### Address for correspondence:

Dr. Sonam Sharma, H. No.12-B, Medical Enclave, KCGMC, Karnal - 132 001, Haryana, India. Phone: 09999841393.  
E-mail: drsonamsharma@gmail.com

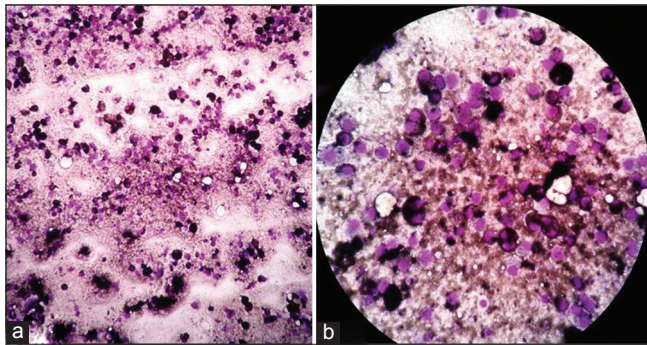
Received: 14-12-2017

Revised: 22-12-2017

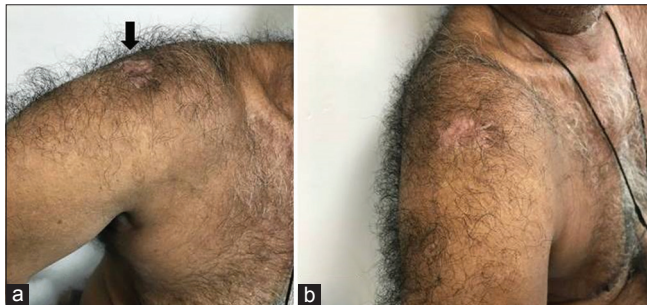Accepted: 15-1-2018



**Figure 1:** (a) Right-sided axillary swelling on clinical inspection. (b) Large, fixed, painless axillary mass



**Figure 2:** (a) Highly cellular cytosmears (May-Grunwald-Giemsa [MGG],  $\times 100$ ). (b) Pleomorphic cells with both intracellular and extracellular melanin pigment (MGG,  $\times 400$ )



**Figure 3:** (a) Scar mark on the right arm with the underlying axillary mass. (b) Irregular scar on reevaluation

is higher in males, and usually, it presents in older age groups, mainly the fourth to fifth decade, like in our case. Different theories have been proposed to explain the absence of a primary lesion in these patients, including spontaneous regression of the primary tumor due to immune mechanisms, *de novo* origin of melanomas in tissues lacking melanocytes, and an unrecognized primary lesion.<sup>[8]</sup> Dasgupta *et al.*<sup>[9]</sup> have documented that ectopic benign nevus cells have been found in lymph nodes and other tissues which can give rise to MM. This finding has been supported by Shenoy *et al.*<sup>[10]</sup> who have reported melanoma arising from nevus cells in a lymph node. Few researchers have also documented that, in most cases where the primary tumor could be identified initially, the history was that of an previously excised pigmented lesion. Following it, one may see either a hypopigmented area or an irregular flat-pigmented scar at the site of excision.<sup>[1]</sup> In our case, the patient had a scar on his right arm after being operated for a blackish-brown-colored patch. We suspected it to be the primary lesion which now has presented as an axillary mass due to axillary lymph node metastasis; however, no confirmatory

reports were available. Schlagonhauff *et al.*<sup>[6]</sup> have also presumed in their study that the majority of these lymph node metastasis develop from a subsequently regressing melanoma of the skin located in the anatomic area drained by the affected lymphatic basin. Therefore, they have suggested that the initial search for a primary tumor in these patients be restricted to an inspection of the entire skin and the adjacent mucosa as well as a detailed examination of the areas drained by the affected lymphatic basin should be done, while in patients with only visceral metastasis, a more extensive workup should be performed.

The diagnosis of MM is usually established by histopathology of the excised specimen which needs to be confirmed by using various immunostains, since a routine hematoxylin and eosin examination may lead to a differential diagnosis of poorly differentiated carcinoma.<sup>[11,12]</sup> Among the various immunohistochemical markers, two of the following immunoperoxidase markers (i.e., S-100, KBA.62, HMB-45, or Melan-A) are required to be positive for a confirmatory diagnosis of MM.<sup>[1]</sup> Electron microscopy significantly contributes to its diagnosis, especially in cases where immunohistochemistry is non-contributory, by an ultrastructural demonstration of melanosomes which is a conclusive feature of MM.<sup>[3]</sup> Nevertheless, a proper clinical workup including history and physical examination plays a significant role in these patients. FNAC is usually done for metastatic lesions, especially in cases of lymph node metastasis. Although biopsy is considered more superior in terms of more tissue for analysis, relation of the tumor with the overlying skin and immunohistochemistry for cell lineage but in cases like these where a primary tumor is unknown and it presents as lymph node metastasis, FNAC is a boon as it is a cost-effective, rapid, and a reliable technique for diagnosis and ancillary testing.<sup>[1,5,13,14]</sup> Cytologically, MM is a highly pleomorphic tumor and needs to be distinguished from anaplastic carcinoma, high-grade non-Hodgkin's lymphoma, and pleomorphic sarcoma.<sup>[5]</sup> These tumors can be ruled out because of the presence of an abundant amount of melanin pigment and presence of intranuclear inclusions in MM.<sup>[13]</sup> In cases of amelanotic melanoma, intranuclear inclusions and a detailed clinical history usually aid in an accurate diagnosis.<sup>[13,15]</sup> Other important investigation for the evaluation of patients suspected to have metastatic MM from an unknown primary includes imaging such as computed tomography or 2-deoxy-2-[fluorine-18] fluoro-D-glucose positron emission tomography to determine the extent of metastatic disease.<sup>[16,17]</sup> Our patient was lost to follow up, and therefore, imaging as well as histopathological confirmation of the diagnosis could not be done and the diagnosis was mainly based on cytology.

The treatment options for patients with MM from an unknown primary site include surgery, radiation, and/or systemic therapy. The mainstay surgery for the patients like in our case is a lymphadenectomy or lymph node dissection. Lee *et al.*<sup>[18]</sup> found improved survival in patients after lymphadenectomy from a nodal metastasis from an unknown primary melanoma. Their research showed a 5-year survival of 55% in patients after lymph node dissection compared at 27% in patients without lymph node dissection. The role of radiation therapy is still controversial. The suggested indications for radiotherapy include evidence of extracapsular spread, multiple lymph nodes, large lymph nodes greater than 3 cm, recurrent disease, and in patients whom lymph node dissection or systemic therapies are not suitable.<sup>[19]</sup> Adjuvant

treatments including chemotherapy and immunotherapy have been looked upon. However, most of these have no effect on the improvement of patients with melanoma from unknown primary site when compared with those of a known primary site.

The prognosis of MM with an unknown primary is still debatable, some studies indicate that there is no difference in the clinical course and prognosis when compared to cases where the primary tumor has been identified,<sup>[6]</sup> while others have documented that metastatic MM with an unknown primary seems to have a better prognosis as compared to those with a known primary.<sup>[20]</sup> Overall, Barth *et al.*<sup>[21]</sup> have reported a median survival ranging from 24 to 127 months in patients with nodal disease, as compared to a range of 3–13.2 months in patients with visceral metastasis. However, relapse rates are high (45–65%), with most recurrences occurring within 2 years of treatment.<sup>[8]</sup>

## CONCLUSION

The aim of presenting this case is to spread awareness of considering MM as one of the important differential diagnoses in patients presenting with an axillary mass and having a previous history of unidentified mass excision. FNAC of such masses can help in the early diagnosis, as these masses which are actually palpable lymphadenopathy can be the first manifestation or recurrence of an underlying widespread disease. A multidisciplinary approach with a proper history, clinical examination, cytological, and histopathological correlation is advisable in such cases for clinching an accurate diagnosis as well as to avoid any diagnostic confusion and therapeutic delay.

## REFERENCES

- Engin B, Erkul B, Ozguzer A, Kaypak MA, Degirmenci M, Akar H. A case of metastatic malignant melanoma presenting with large axillary mass and massive ascites mimicking hematologic malignancy. *FNG Bilim Tıp Dergisi* 2016;2:138-41.
- Elder DE, Elenitsas R, Murphy GF, Xu X. Benign pigmented lesions and malignant melanoma. In: Elder DE, Johnson B, Elenitsas R, editors. *Lever's Histopathology of the skin*. 9<sup>th</sup> ed. Philadelphia, PA: JB Lippincott; 2005. p. 715-803.
- Moorchung N, Mukherjee B, Srinivas V, Subramanya H. Metastatic amelanotic malignant melanoma with unknown primary - A case report. *Med J Armed Forces India* 2004;60:295-6.
- Zbytek B, Carlson JA, Granese J, Ross J, Mihm MC Jr., Slominski A, *et al.* Current concepts of metastasis in melanoma. *Expert Rev Dermatol* 2008;3:569-85.
- Singla S, Sharma S, Khambra P, Singla G. Cytodiagnosis of an unsuspected case of metastatic malignant melanoma. *Rec Adv Path Lab Med* 2016;2:2-3.
- Schlagonhauff B, Strodoel W, Ellwanger U, Meici F, Zimmermann C, Breuninger H. Malignant melanoma of unknown primary origin. *Cancer* 1997;80:60-5.
- Velez A, Walsh D, Karakousis CP. Treatment of unknown primary melanoma. *Cancer* 1991;68:2579-81.
- Kamposioras K, Pentheroudakis G, Pectasides D, Pavlidis N. Malignant melanoma of unknown primary site. To make the long story short. A systematic review of the literature. *Crit Rev Oncol Hematol* 2011;78:112-26.
- Dasgupta T, Bowden L, Berg JW. Malignant melanoma of unknown primary origin. *Surg Gynecol Obstet* 1963;117:341-5.
- Shenoy BV, Fort L 3<sup>rd</sup>, Benjamin SP. Malignant melanoma primary in lymph node. The case of the missing link. *Am J Surg Pathol* 1987;11:140-6.
- Liang KV, Sanderson SO, Nowakowski GS, Arora AS. Metastatic malignant melanoma of the gastrointestinal tract. *Mayo Clin Proc* 2006;81:511-6.
- Sharma S, Dawson L. A rare tumor with a very rare initial presentation: Thymic carcinoma as bone marrow metastasis. *Case Rep Pathol* 2017;2017:6497376.
- Orell SR, Sterrett GF, Walters MN, Whitaker D. Skin, subcutis and soft tissues. In: *Manual and Atlas of Fine Needle Aspiration Cytology*. 3<sup>rd</sup> ed. New York: Churchill Livingstone; 1999. p. 371-400.
- Mannan R, Piplani S, Sharma S, Manjari M, Gupta S. Cytological correlation of spectrum of head and neck lesions with epidemiological and diagnostic parameters. *Indian J Pathol Oncol* 2017;4:92-7.
- Rosai J. *Rosai and Ackerman's Surgical Pathology*. 10<sup>th</sup> ed. New York: Mosby Elsevier; 2005.
- Steinert HC, Huch Böni RA, Buck A, Böni R, Berthold T, Marinček B, *et al.* Malignant melanoma: Staging with whole-body positron emission tomography and 2-[F-18]-fluoro-2-deoxy-D-glucose. *Radiology* 1995;195:705-9.
- Bankar S, Patkar S, Desai S, Shrikhande SV. Unusual presentation of melanoma of unknown primary origin: A case report and review of literature. *J Can Res Ther* 2015;11:1025.
- Lee CC, Faries MB, Wanek LA, Morton DL. Improved survival for stage IV melanoma from an unknown primary site. *J Clin Oncol* 2009;27:3489-95.
- Walton B, McCammon S, Quinn FB Jr., Quinn MS. Metastatic Melanoma of Unknown Primary: A Unique Entity? Grand Rounds Presentation, Department of Otolaryngology. Galveston, TX: The University of Texas Medical Branch (UTMB Health); 2012.
- Vijuk G, Coates AS. Survival of patients with visceral metastatic melanoma from an occult primary lesion: A retrospective matched cohort study. *Ann Oncol* 1998;9:419-22.
- Barth A, Wanek LA, Morton DL. Prognostic factors in 1,521 melanoma patients with distant metastases. *J Am Coll Surg* 1995;181:193-201.

**How to cite this Article:** Garg S, Sharma S. Metastatic malignant melanoma from an unknown primary presenting as an axillary mass. *Asian Pac. J. Health Sci.*, 2018; 5(1):25-27.

**Source of Support:** Nil, **Conflict of Interest:** None declared.