

Post Cholecystectomy Stump Calculus Cholecystitis with Completion Cholecystectomy –A**Rare Case Report****GD Yadav, Ajay Kumar****Department of Surgery, GSVM Medical College, Kanpur, U.P., India***Received: 12-10-2019 / Revised: 25-12-2019 / Accepted: 05-01-2020****ABSTRACT**

Cholecystectomy is the most common method of choice for treating symptomatic gall stones. It can either be performed laparoscopically or by open cholecystectomy. Partial cholecystectomy is usually done whenever there is difficulty in performing total cholecystectomy due to various reasons such as acute attack with adhesions, fibrosis, in view of preventing bile duct and vascular injuries, variations in anatomy which lead to bile duct remnant which can cause post cholecystectomy syndrome. After a partial or subtotal cholecystectomy, symptoms may recur from pathology in the gallbladder remnant. When this occurs, a completion cholecystectomy is required as treatment of choice. We here report a case of a patient with stump cholecystitis in a gallbladder remnant to demonstrate open completion cholecystectomy.

Key words: Cholecystectomy, case, anatomy

©2020The Author(s). This is an open access article distributed under the terms of the Creative Commons Attribution License (<http://creativecommons.org/licenses/by/4.0/>), which permits unrestricted use, distribution, and reproduction in any medium, provided the original work is properly cited.

INTRODUCTION

Cholecystectomy, either laparoscopically or by the conventional ‘open’ method, is considered to be the “gold standard” operation for gallstones.^[1] Partial cholecystectomy has been performed in many situations such as difficult Calot’s triangle, where the anatomy may be distorted by recurrent episodes of inflammation, adhesions or bleeding. In such a situation, persisting with dissection in the Calot’s triangle can lead to major complications such as common bile duct and/or vascular injury, which can turn the procedure into a nightmare, both for the surgeon as well as the patient. In such cases, it is advisable to leave a cuff of the gallbladder near the Hartmann’s pouch, removing the rest of the gallbladder, in the manner described by Lerner^[2] or Bornman and Terblanche^[3] after removing all stones from the remaining cuff of the gallbladder. However, this carries the risk of developing stump cholecystitis when the gallbladder remnant becomes inflamed due to stone disease.^[4]

The reported incidence of stump cholecystitis varies but has been reported to occur in as many as 5% of patients after emergent cholecystectomy, and it is rare after elective operations. It tends to occur in middle aged women who are usually quite confident that their symptoms are similar to those that prompted their original chole-cystectomy.^[4] The diagnosis is always into the dilemma as history suggestive of symptoms of post cholecystectomy syndromes leading to delayed diagnosis. Contrast enhanced CT scan or MRCP further aids in definitive diagnosis. ERCP can help in the diagnosis and if possible stones in the cystic duct remnant can be taken out with great difficulty. Most of the patients with retained calculi require surgical intervention and re exploration to remove the cystic duct remnant and stones.

CASE REPORT

43-year-old female with presented to our hospital complaining of severe right upper quadrant pain and vomiting. He reported having open cholecystectomy done 14 years before. Now she noted that the symptoms he now experienced were similar. Operative notes were not available but she reported that the operation was uncomplicated and she was discharged 3day after open surgery. Liver function panel and serum amylase levels were normal.

Address for Correspondence

Dr. Ajay KumarDepartment of Surgery, GSVM Medical College,
Kanpur, U.P., India.**E-mail:** ajjumramc@gmail.com

Abdominal ultrasound suggested that post cholecystectomy status with stones were present in cystic duct size 8.2 mm and 8.1 mm and normal CBD. The patient's history was revisited on this presentation. She insisted that open cholecystectomy was performed 14 years before and there was a surgical scar at the right upper quadrant, but no operative records or histology reports were available to corroborate the surgical history. CT finding are prominent gall bladder stump with radio opaque stone. [Figure 1]. She was prepared for general anaesthesia and taken to the operating theatre for open completion cholecystectomy. Open shears were used to perform adhesiolysis in order to visualize the structures in the right upper quadrant. There were dense adhesions at gallbladder bed precluding clear visualization of relevant anatomy [Figure 2]. Careful and patient dissection presented the gallbladder remnant. The remnant was followed in an antegrade fashion down to the cystic duct to demonstrate cystic stump. The cystic duct and artery were then individually ligated and the gallbladder separated completely. Cystic stump and stone remove [Figure 3]. Her recovery was uneventful and she was discharged home after 3day

DISCUSSION

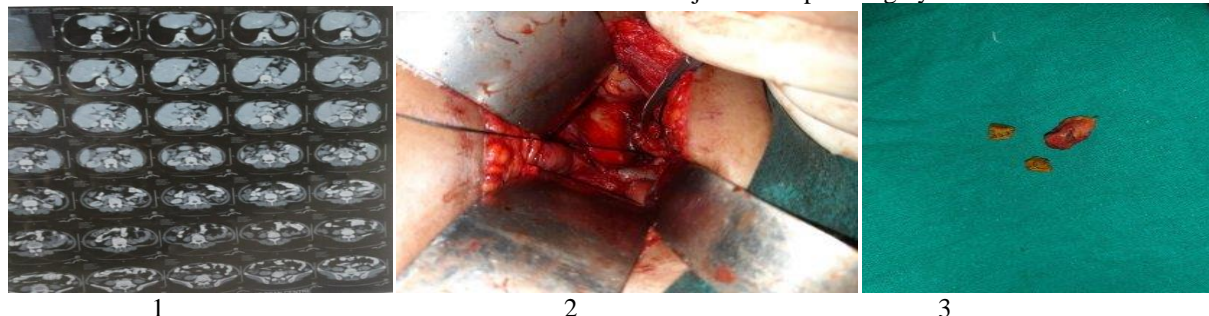


Figure 1: CT finding are prominent gall bladder stump with radio opaque stone

Figure 2: Clear visualization of relevant anatomy; Figure 3: Cystic stump and stone remove

CONCLUSION

Post cholecystectomy stump calculus cholecystitis is important but rare sequelae after cholecystectomy. Completion cholecystectomy (open or laparoscopic) is the most common treatment modality reported in the literature for the management of residual gallbladder stump with stones.

REFERENCES

1. Mayank Jayant, Robin Kaushik. Presentation and management of gallbladder remnant after partial cholecystectomy; Tropical Gastroenterology 2013; 34(2):99-10.
2. Lerner AI. Partial cholecystectomy. Can Med Assoc J. 1950;63:54-6.
3. Bornman PC, Terblanche J. Subtotal cholecystectomy: for the difficult gallbladder in portal hypertension and cholecystitis. Surgery. 1985;98:1-6.

A subtotal cholecystectomy is a safe option in the face of severe inflammation at Calot's triangle because it reduces the potential for common duct injury. However, this carries the risk of developing stump cholecystitis when the gallbladder remnant becomes inflamed due to stone disease.^[5] The reported incidence of stump cholecystitis varies but has been reported to occur in as many as 5% of patients after emergent cholecystectomy, and it is rare after elective operations. It tends to occur in middle-aged women who are usually quite confident that their symptoms are similar to those that prompted their original cholecystectomy. Despite a suggestive history, the diagnosis is often delayed due to a low index of suspicion. Therefore clinicians should consider this diagnosis, especially after thorough investigations have excluded alternate pathologies. Once the diagnosis is confirmed, the definitive treatment is a reoperation to excise the gallbladder remnant at a completion cholecystectomy.^[5] These are technically difficult operations because there is usually significant scarring and anatomic distortion at the gallbladder bed.^[5] Because a laparoscopic approach was thought to be unsafe in this circumstance, many patients were traditionally subjected to open surgery.

4. A. K. Parmar, R.G.Khandelwal, M. J. Mathew, and P.K.Reddy, "Laparoscopic completion cholecystectomy: a retrospective study of 40 cases, Asian Journal of Endoscopic Surgery, 2013; 6(2):96-99
5. K. Chowbey, S. K. Bandyopadhyay, A. Sharma, R. Khullar, V. Soni, M. Baijal, "Laparoscopic reoperation for residual gallstone disease," Surgical Laparoscopy, Endoscopy and Percutaneous Techniques, 2003;13(1):31-35.

How to cite this Article: Yadav GD, Kumar A. Post Cholecystectomy Stump Calculus Cholecystitis with Completion Cholecystectomy –A Rare Case Report. Asian Pac. J. Health Sci., 2020; 7(1):13-14.

Source of Support: Nil, **Conflict of Interest:** None declared.